Conceptual Radiology

Radiological Anatomy: Practice Cases

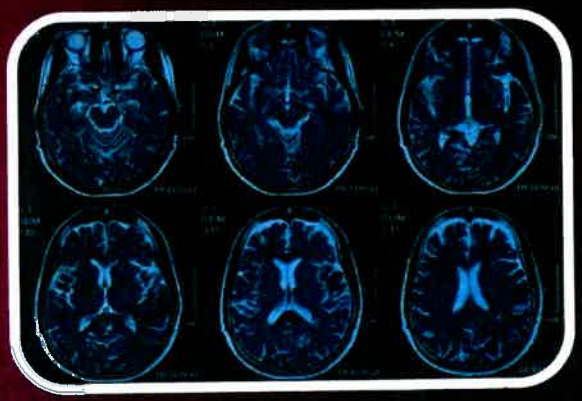

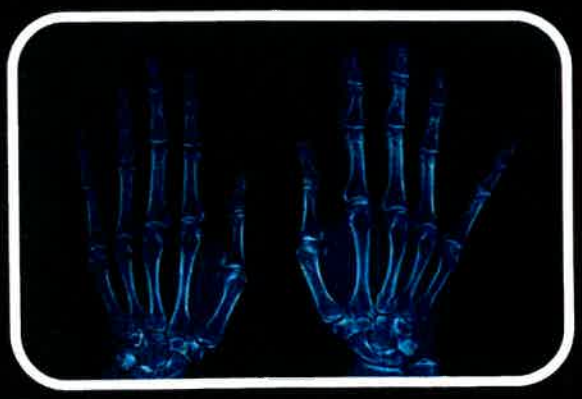

Authored By The Faculty of Conceptual Radiology

Radiological Anatomy: Practice Cases



Table of Content

Chapter Name	Page No.
1. Radiological Anatomy: Brain & Head-Neck	1
2. Radiological Anatomy: Thorax	19
3. Radiological Anatomy: Musculoskeletal System	26
4. Radiological Anatomy: Abdomen	36

Radiological Anatomy: Brain & Head-Neck

Image - 1

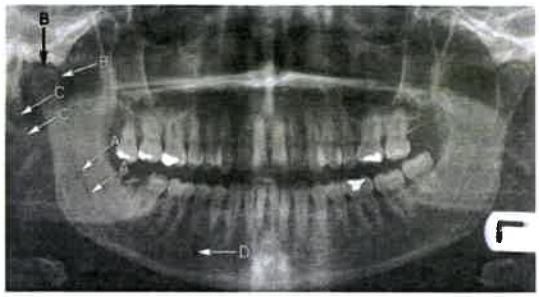

Orthopantomogram (OPG)

A. Right inferior alveolar canal.
B. Right mandibular condyle.
C. Right styloid process.
D. Right mental foramen.

Image - 2

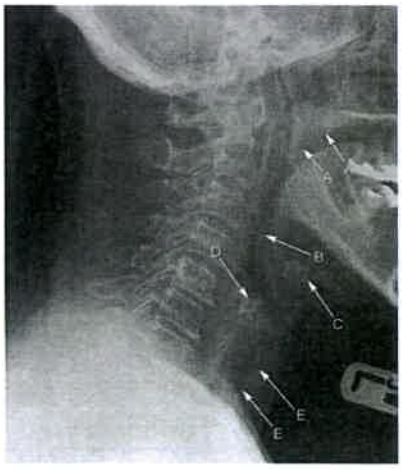

A. Soft palate.
B. Epiglottis.
C. Hyoid bone.
D. Thyroid cartilage.
E. Trachea.

Image - 3

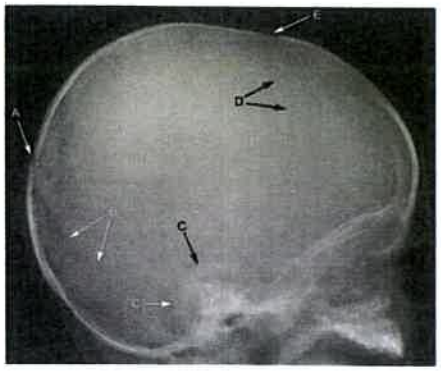

Lateral X-ray of skull

A. Posterior fontanelle.
B. Lambdoid suture.
C. Pinna.
D. Coronal suture.
E. Anterior fontanelle.

Image - 4

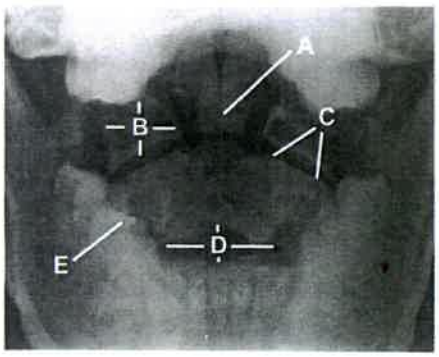

A. Dens (odontoid peg) of C2
B. Lateral mass of C1
C. Superior articular facet of C2
D. C2–3 interspace
E. Reparative 'filling' in left lower molar tooth

Image - 5

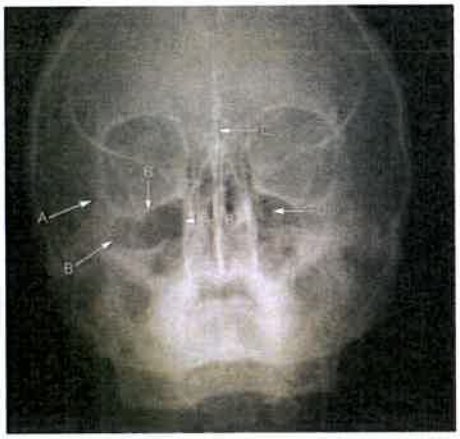

PA X-ray of the skull

A. Frontal process of the right zygomatic bone.
B. Right maxillary antrum.
C. Crista galli.
D. Left foramen rotundum.

Image - 6

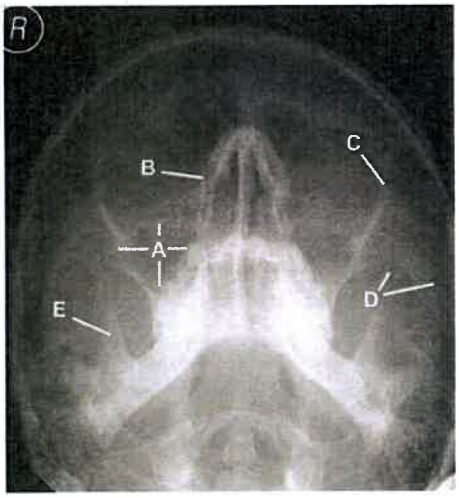

A. Maxillary sinus
B. Lamina papyracea
C. Fronto-zygomatic suture
D. Zygomatic arch
E. Coronoid process of mandible

Image - 7

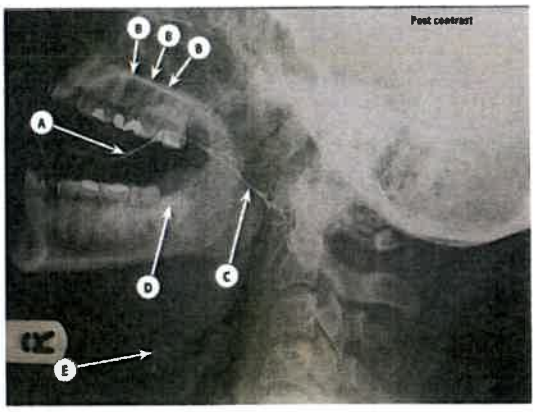

A. Catheter with contrast
B. Palatine process of maxilla
C. Oral vestibule opposite to the second upper molar tooth
D. Crown of unerupted right inferior third molar tooth (right lower eighth tooth)
E. Body of the hyoid bone

Image - 8

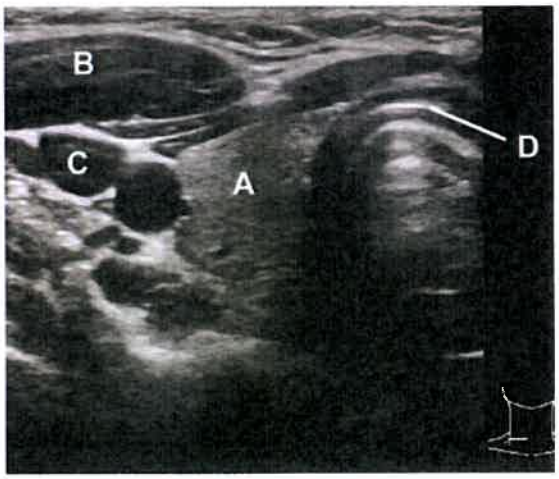

A. Right lobe of thyroid
B. Sternocleidomastoid muscle
C. Internal jugular vein
D. Tracheal ring

Image - 9

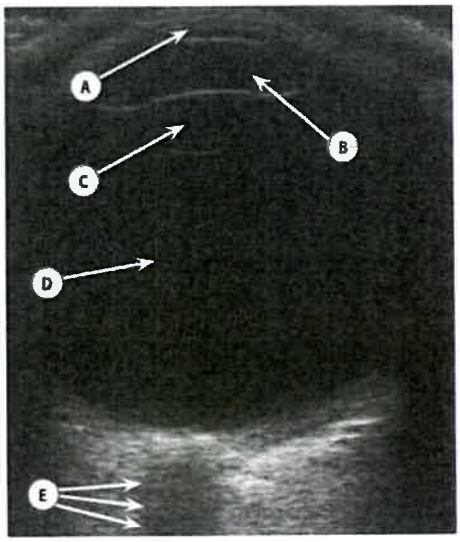

A. Cornea
B. Aqueous humour
C. Lens
D. Vitreous humour
E. Optic sheath

Image - 10

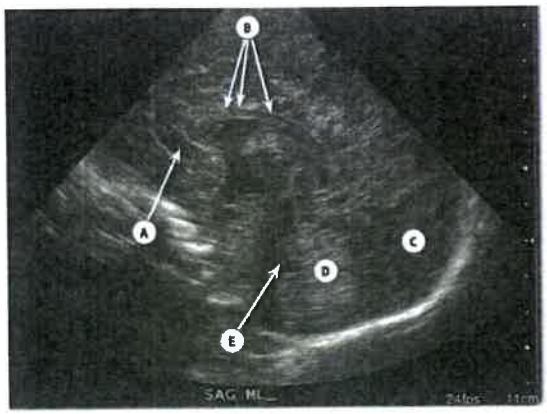

A. Cingulate gyrus
B. Body of corpus callosum
C. Occipital lobe
D. Cerebellum
E. Fourth ventricle

Image - 11

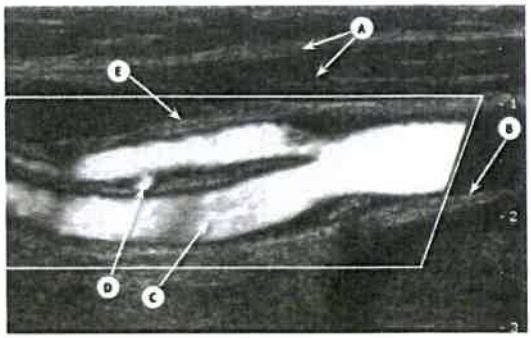

A. Sternocleidomastoid muscle fibres
B. Intima of the common carotid artery
C. Internal carotid artery
D. Ascending pharyngeal artery
E. Adventitia of the external carotid artery

Image - 12

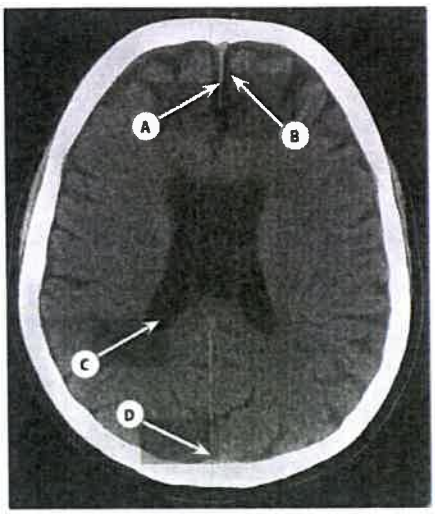

A. Falx cerebri
B. Interhemispheric fissure
C. Occipital horn of the right lateral ventricle
D. Superior sagittal sinus

Image - 13

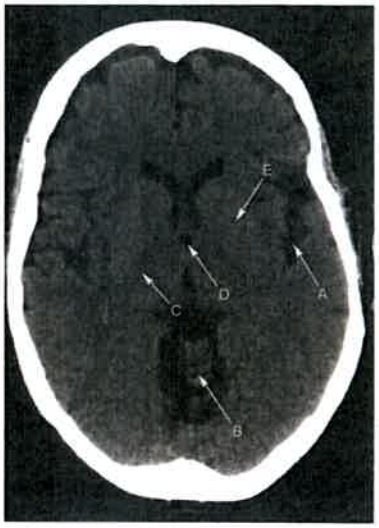

Axial CT of the brain

A. Left sylvian fissure.
B. Cerebellar vermis.
C. Posterior limb of the right internal capsule.
D. Third ventricle.
E. Left lentiform nucleus.

Image - 14

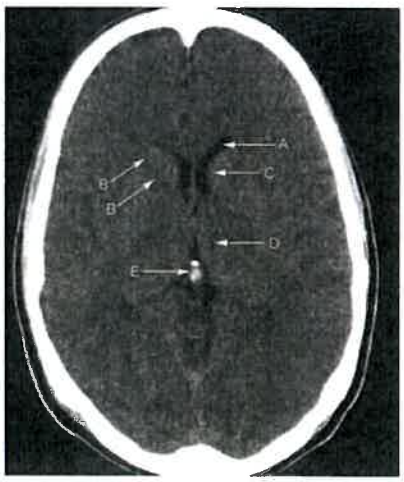

A. Frontal horn of the left lateral ventricle.
B. Anterior limb of the right internal capsule.
C. Head of the left caudate nucleus.
D. Left thalamic nucleus.
E. Pineal gland.

Image - 15

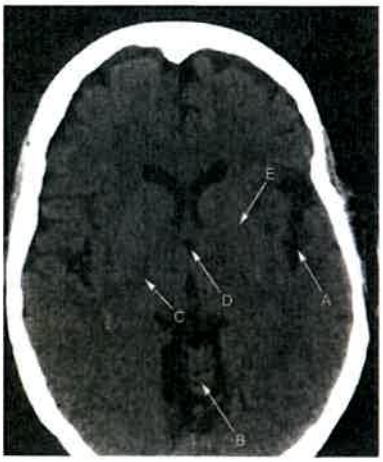

Axial CT of the brain

A. Sylvian fissure
B. Cerebellar vermia
C. Right internal capsule
D. Foramen of Monro
E. Left Putamen

Image - 16

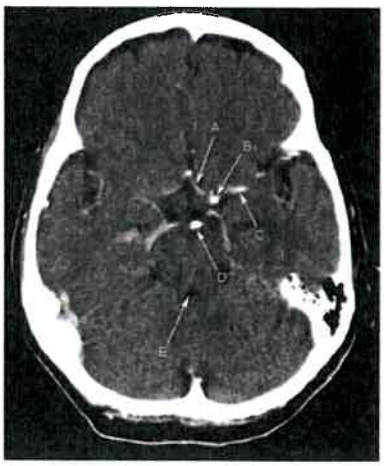

Axial CT of the brain with IV contrast

A. Left anterior cerebral artery.
B. Left internal carotid artery.
C. Left middle cerebral artery.
D. Basilar artery
E. Aqueduct of Sylvius.

Image - 17

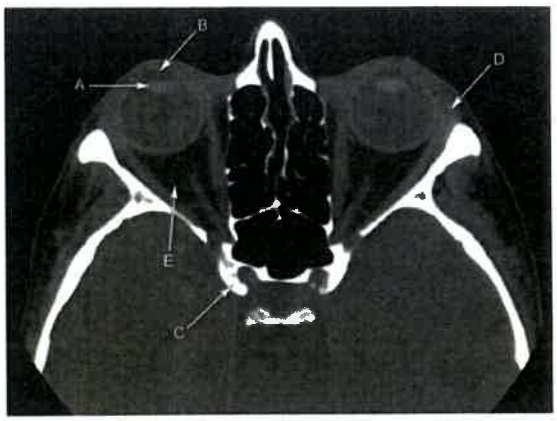

Axial CT of the orbits

A. Right lens.
B. Right cornea.
C. Right anterior clinoid process.
D. Inferior pole of the left lacrimal gland.
E. Right intraconal fat.

Image - 18

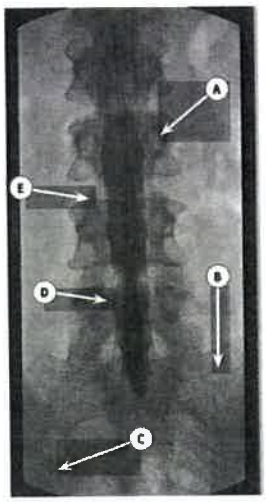

A. Left pedicle of L3
B. Left sacral alum
C. Right sacro-iliac joint
D. Right L5 nerve root
E. Right superior articular process of L4

Image - 19

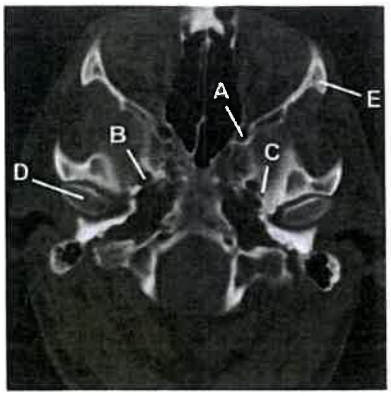

A. Foramen rotundum
B. Foramen ovale
C. Foramen spinosum
D. Condylar process of the mandible
E. Frontal process of the zygoma

Image - 20

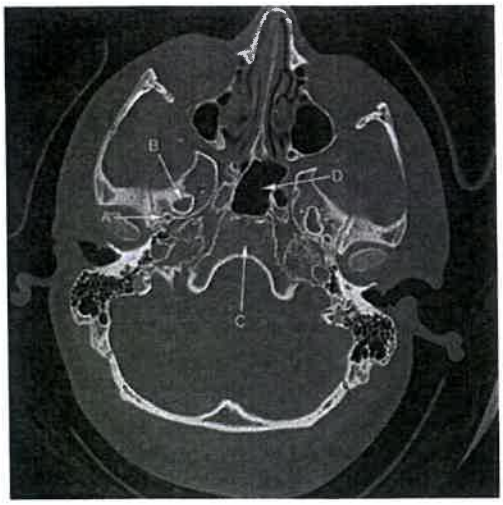

A. Right foramen spinosum.
B. Right foramen ovale.
C. Clivus.
D. Sphenoid sinus.

Image - 21

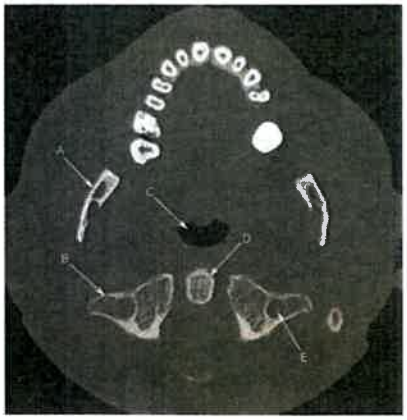

Axial CT of the cervical spine

A. Right mandible.
B. Right transverse process of atlas (C1).
C. Nasopharynx
D. Dens
E. Left foramen transversarium

Image - 22

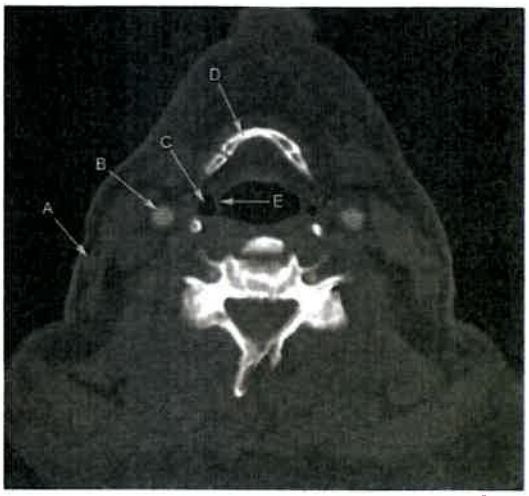

Axial CT of the neck with IV contrast

A. Right external jugular vein.
B. Right common carotid artery.
C. Right piriform fossa.
D. Hyoid bone.
E. Right aryepiglottic fold.

Image - 23

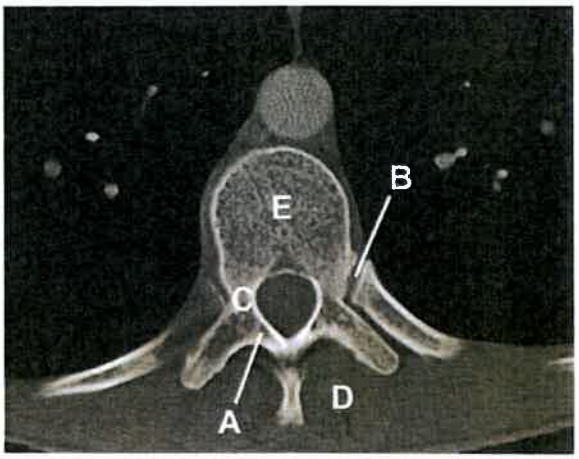

A. Lamina
B. Costovertebral joint
C. Pedicle
D. Erector spinae muscles
E. Vertebral body

Image - 24

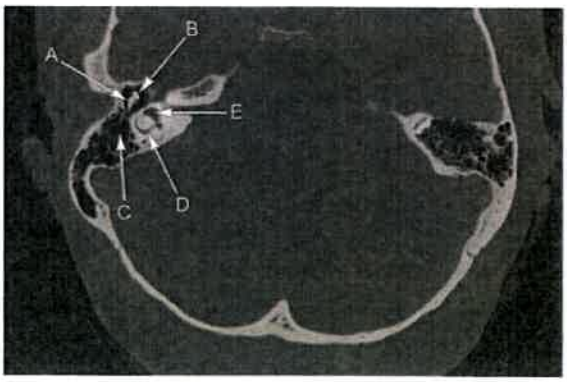

Axial CT of the auditory canal

A. Right incus.
B. Right malleus.
C. Right mastoid air cells.
D. Right semicircular canal.
E. Right vestibule.

Image - 25

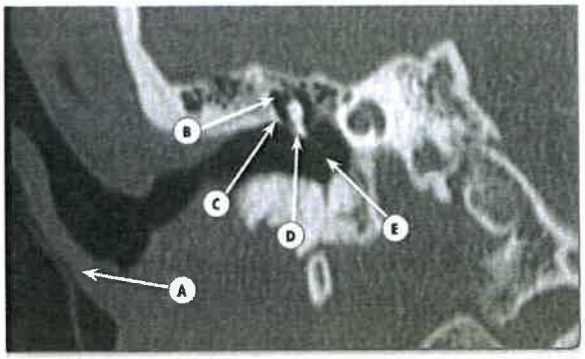

A. Pinna of the right ear
B. Epitympanum
C. Scutum
D. Manubrium of the malleus
E. Tympanic membrane

Image - 26

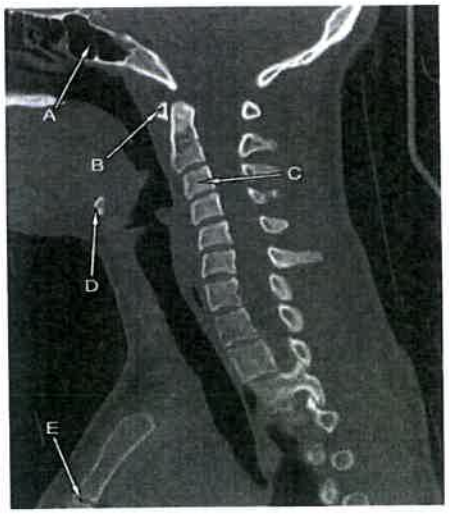

A. Sphenoid sinus
B. Anterior arch of atlas
C. Body of C3 vertebra
D. Hyoid bone
E. Manubrio-sternal joint

Image - 27

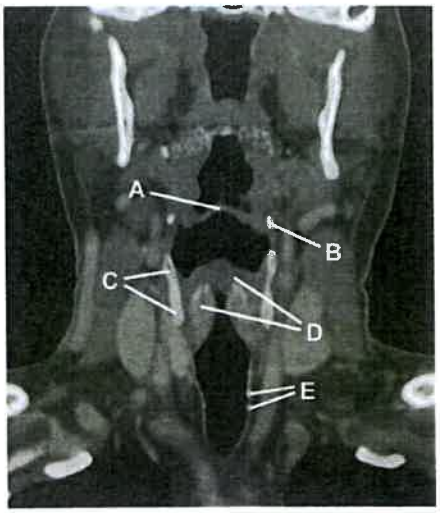

A. Epiglottis
B. Greater horn of hyoid bone
C. Thyroid cartilage
D. Vocal cords
E. Tracheal rings

Image - 28

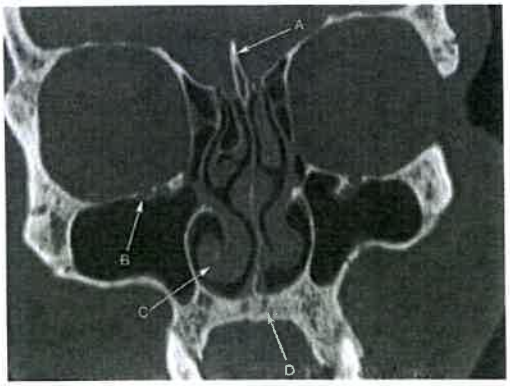

A. Crista galli.
B. Right infraorbital foramen.
C. Right inferior turbinate.
D. Hard palate.

Image - 29

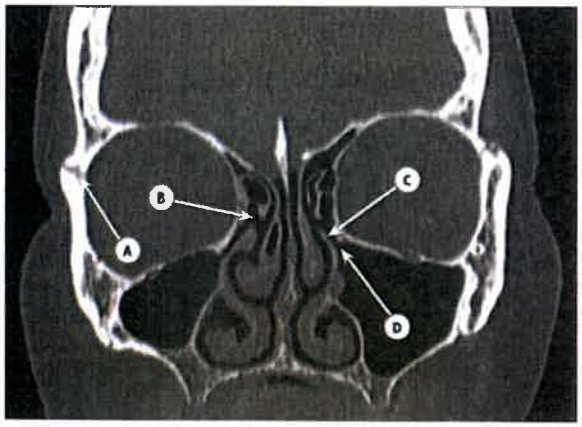

A. Right frontozygomatic suture
B. Right ethmoid infundibulum
C. Left uncinate process
D. Left maxillary sinus ostium

Image - 30

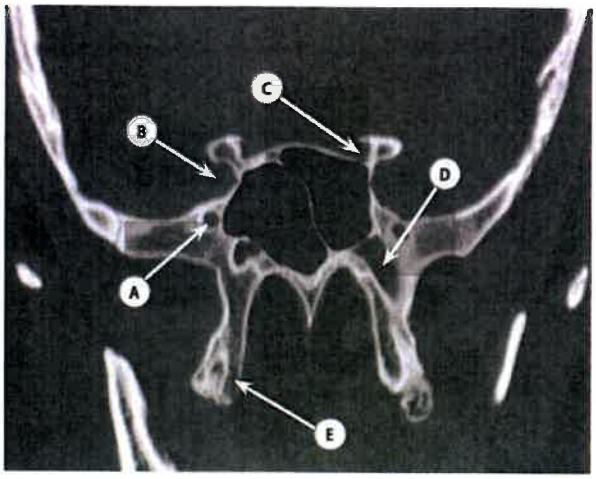

A. Right foramen rotundum
B. Right superior orbital fissure
C. Left optic canal
D. Left pterygopalatine fossa
E. Right medial pterygoid plate

Image - 31

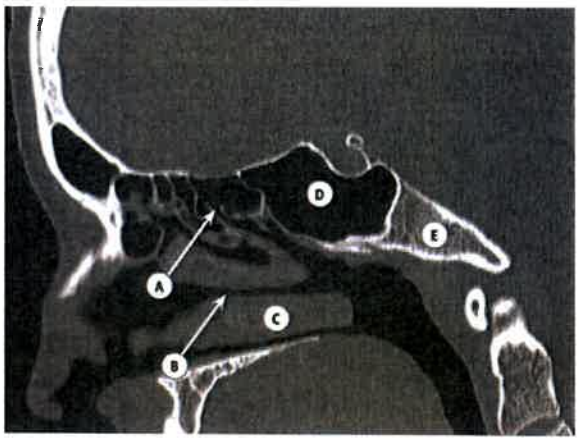

A. Posterior ethmoid ostium
B. Middle meatus
C. Inferior turbinate (concha)
D. Sphenoid sinus
E. Clivus

Image - 32

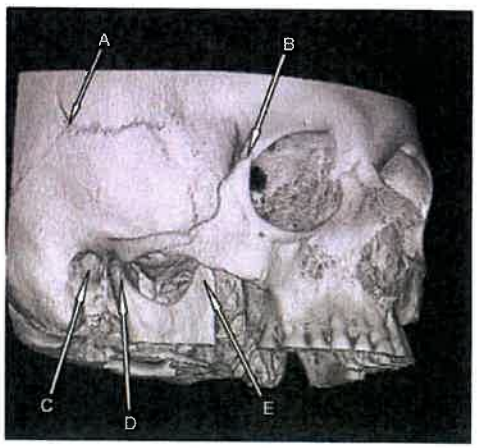

A. Right pterion
B. Right fronto-zygomatic suture
C. Right external acoustic meatus of temporal bone
D. Right condyle of mandible
E. Right coronoid process mandible

Image - 33

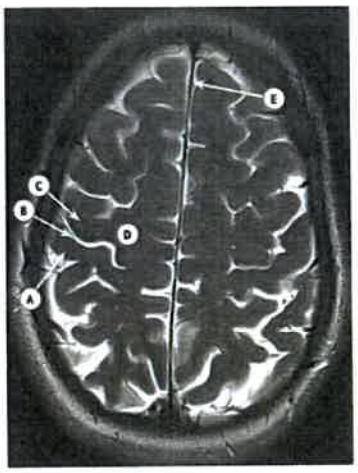

A. Right postcentral gyrus
B. Right central sulcus (of Rolando)
C. Right precentral gyrus
D. Centrum semiovale
E. Interhemispheric fissure

Image - 34

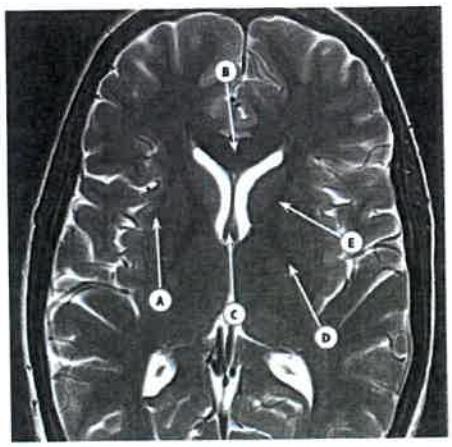

A. Right external capsule
B. Genu of corpus callosum
C. Fornix
D. Posterior limb of left internal capsule
E. Anterior limb of left internal capsule

Image - 35

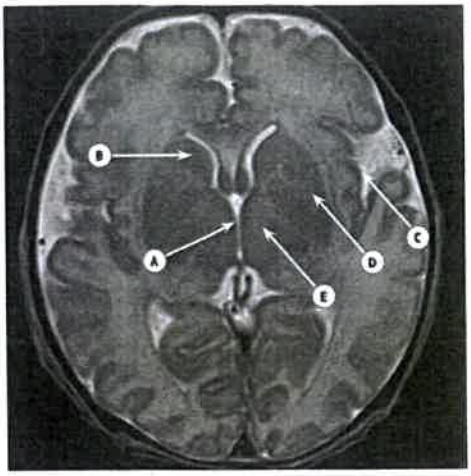

A. Third ventricle
B. Head of the right caudate nucleus
C. Cortex of the left insula
D. Left lentiform nucleus
E. Left hypothalamus

Image - 36

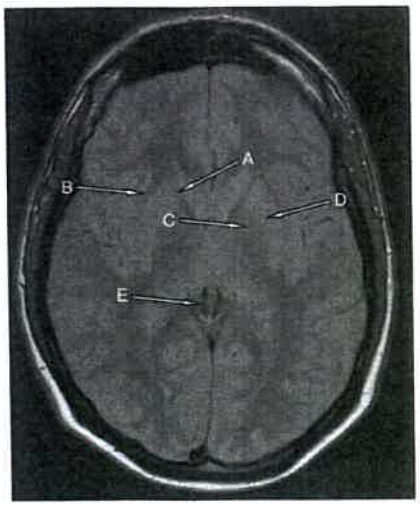

A. Anterior limb of right internal capsule
B. Right external capsule
C. Left globus pallidus
D. Left putamen
E. Internal cerebral vein

Image - 37

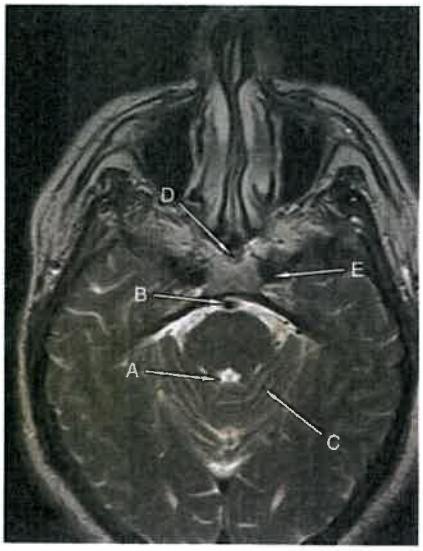

A. Quadrigeminal cistern
B. Basilar artery
C. Cerebellar folia
D. Optic chiasma
E. Left internal carotid artery

Image - 38

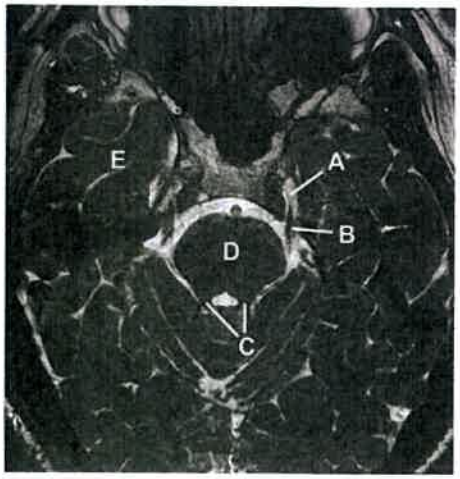

A. Meckel's cave
B. Trigeminal nerve
C. Superior cerebellar peduncles
D. Pons
E. Anterior temporal lobe

Image - 39

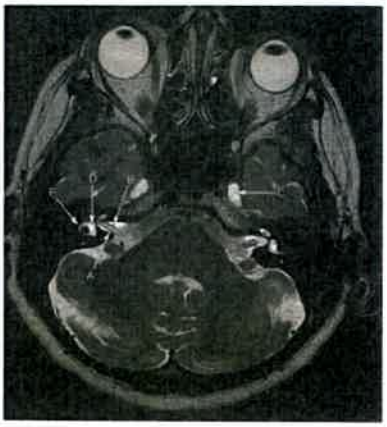

Axial T2 MRI of the brain

A. Vestibulocochlear nerve (CN VIII).
B. Facial nerve (CN VII).
C. Left Meckel's cave.
D. Right vestibule.
E. Right semicircular canal.

Image - 40

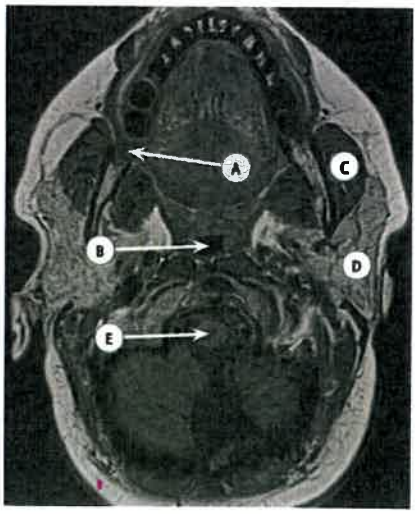

A. Right retromolar trigone
B. Oropharynx
C. Left masseter muscle
D. Superficial lobe of the left parotid gland
E. Cervical spinal cord

Image - 41

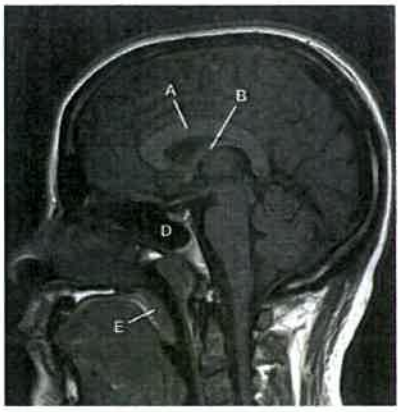

A. body of the corpus callosum
B. Fornix
D. Sphenoid sinus
E. Soft palate

Image - 42

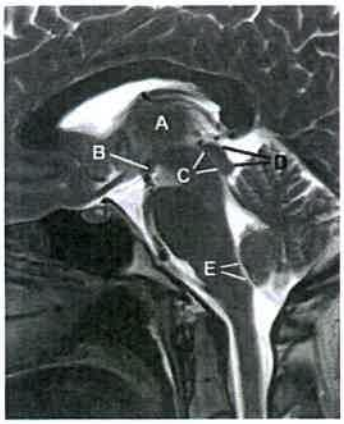

A. Massa intermedia of thalamus
B. Mamillary body
C. Cerebral aqueduct of Sylvius
D. Superior and inferior colliculi
E. Foramen of Magendie

Image - 43

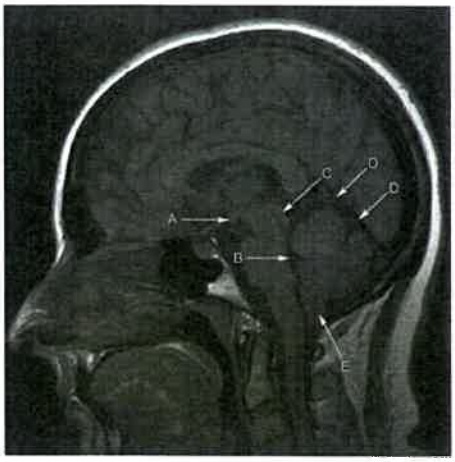

Sagittal T1 MRI of the brain

A. Mammillary body.
B. Fourth ventricle.
C. Tectum of the midbrain.
D. Tentorium cerebelli.
E. Cerebellar tonsil.

Image - 44

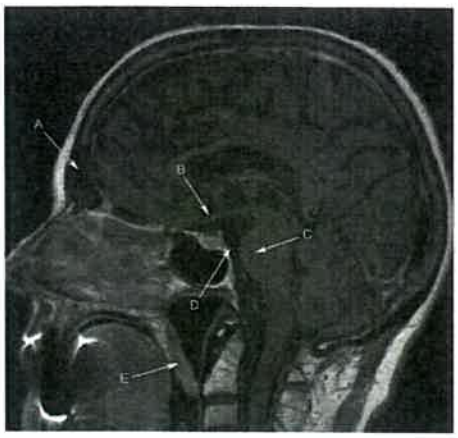

A. Frontal sinus.
B. Optic chiasm.
C. Pons.
D. Prepontine cistern.
E. Soft palate.

Image - 45

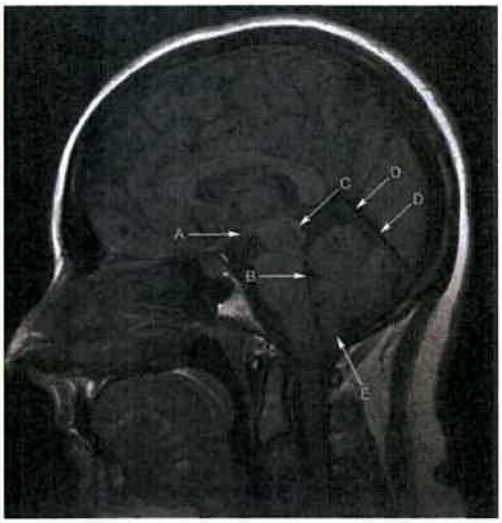

Sagittal T1 MRI of the brain

A. Mammillary body.
B. Fourth ventricle.
C. Tectum of the midbrain.
D. Tentorium cerebelli.
E. Cerebellar tonsil.

Image - 46

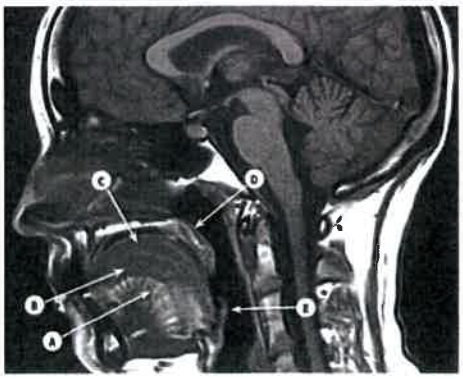

A. Genioglossus muscle
B. Intrinsic transverse muscle of the tongue
C. Intrinsic longitudinal muscle of the tongue
D. Soft palate
E. Epiglottis

Image - 47

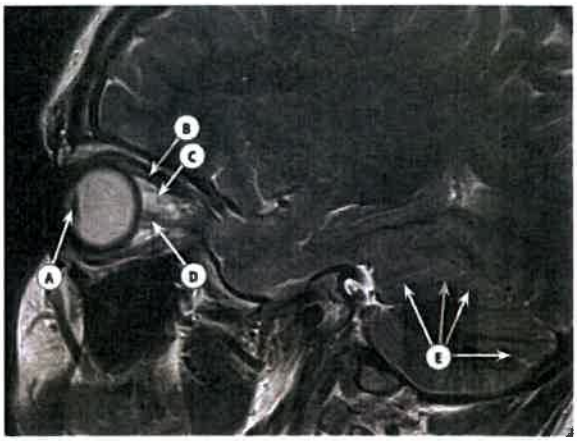

A. Lens
B. Superior rectus muscle
C. Retro-orbital fat
D. Optic nerve
E. Cerebellar folia

Image - 48

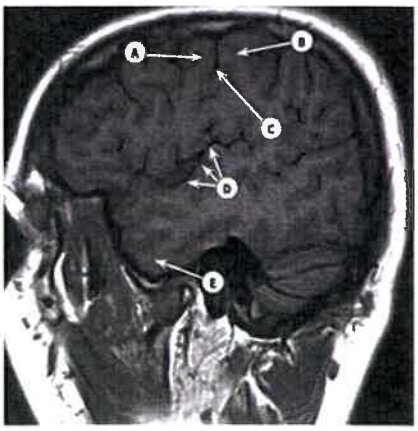

A. Precentral gyrus
B. Postcentral gyrus
C. Central sulcus (Rolandic fissure)
D. Lateral sulcus (Sylvian fissure)
E. Inferior temporal gyrus

Image - 49

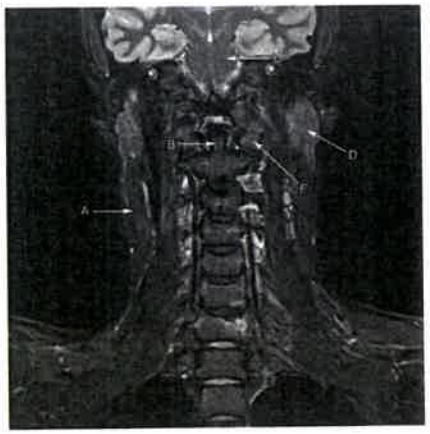

Coronal STIR MRI of the neck

A. Right sternocleidomastoid muscle.
B. Odontoid
C. Pons.
D. Left parotid gland.
E. Left lateral mass of C1.

Image - 50

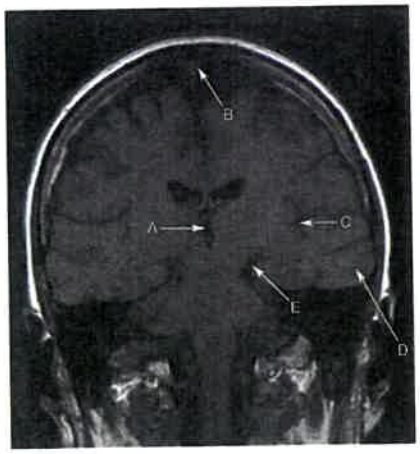

Coronal T1 MRI of the brain

A. Third ventricle.
B. Superior sagittal sinus.
C. Left sylvian fissure.
D. Left temporal lobe.
E. Left ambient cistern.

Image - 51

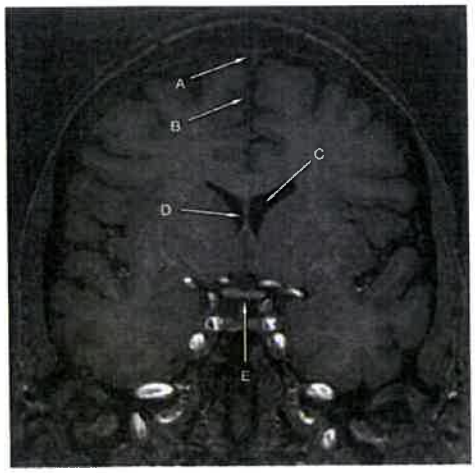

A. Superior sagittal sinus
B. Falx cerebri
C. Left lateral ventricle
D. Septum pellucidum
E. Optic chiasm

Image - 52

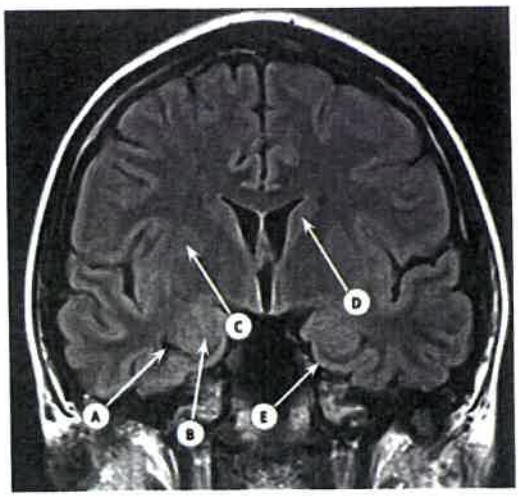

A. Temporal horn of the right lateral ventricle
B. Right hippocampus
C. Right lentiform nucleus
D. Head of the left caudate nucleus
E. Left parahippocampal gyrus

Image - 53

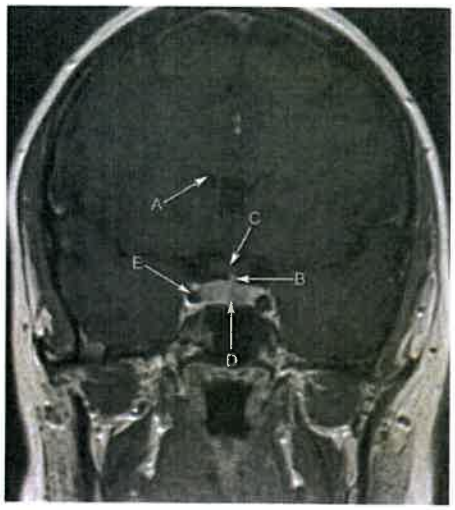

Coronal T1 MRI of the brain with IV contrast

A. Right lateral ventricle.
B. Infundibulum
C. Optic chiasm.
D. Pituitary gland.
E. Right internal carotid artery.

Image - 54

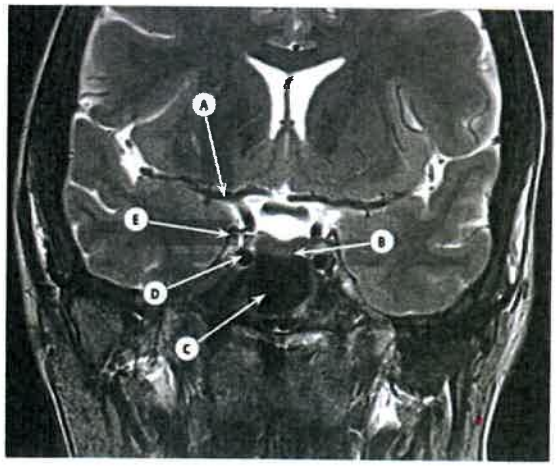

A. Right middle cerebral artery
B. Pituitary gland
C. Sphenoid sinus
D. Cavernous portion of the right internal carotid artery
E. Oculomotor nerve (CN III)

Image - 55

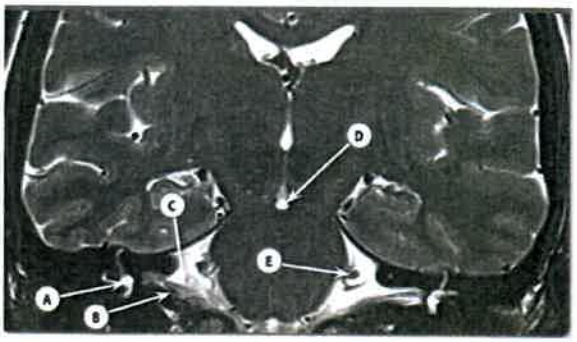

A. Right vestibule
B. Cochlear branch of the right vestibulocochlear nerve (VIII)
C. Right facial nerve (VII)
D. Interpeduncular cistern
E. Left trigeminal nerve (V)

Image - 56



A. Right trigone of lateral ventricle
B. Splenium of corpus callosum
C. Choroid plexus
D. Tentorium cerebelli
E. Cisterna magna